

OLGU SUNUMU CASE REPORT

DOI: 10.31609/jpmrs.2021-82996

Idiopathic Axillary Web Syndrome: A Case Report on a Rare Entity

İdiyopatik Aksiller Web Sendromu: Nadir Görülen Bir Hastalığın Olgu Sunumu

Emine DÜNDAR AHİ^a, Selin OZEN^b, Sacide Nur SARAÇGİL COŞAR^b

^aClinic of Physical Medicine and Rehabilitation, Private Medar Hospital, Kocaeli, TURKEY

^bDepartment of Physical and Rehabilitation Medicine, Başkent University Faculty of Medicine, Ankara, TURKEY

ABSTRACT Axillary web syndrome (AWS) is characterized by a web of fibrotic vein and lymphatic tissue cords in the axillar, shoulder pain and reduced range of motion (ROM). Cases of idiopathic AWS have rarely been reported in the literature; to the best of our knowledge, the case described here is the third. A 29 year old male presented with left sided shoulder pain and reduced ROM and cords in the axilla. A diagnosis of idiopathic AWS was made using diagnostic ultrasound and magnetic resonance imaging and treated using shoulder and arm ROM and strengthening exercises, stretching of shoulder flexors and abductors and cord myofascial release. Physical modalities included infrared, therapeutic ultrasound and transcutaneous electrical nerve stimulation. The patient's shoulder pain, reduced ROM and cords resolved with treatment. A diagnosis of AWS should be considered in patients with shoulder pain and reduced ROM, a detailed shoulder examination is essential. The first line treatment for AWS is yet to be determined; this will ensure its timely management and so avoid the development of chronic shoulder disability.

Keywords: Axillary web syndrome; lymphatic cording; shoulder pain; physical therapy

ÖZET Aksiller web sendromu (AWS), aksiller bölgede ağ şeklinde fibrotik ven ve lenfatik dokular (kording) ile karakterize, omuz ağrısı ve eklem hareket açıklığında (EHA) azalmaya sebep olan bir patolojidir. İdiyopatik AWS hakkında olgu sunumları, literatürde az bulunmaktadır ve burada sunulan olgu, bilimiz dâhilinde literatürdeki 3. olgudur. Yirmi dokuz yaşında erkek hasta, sol taraflı omuz ağrısı ve EHA'da azalmaya eşlik eden aksiller bölgede şerit şeklinde uzanan "kord" belirtisiyle kliniğimize başvurdu. Diagnostik ultrason ve manyetik rezonans görüntülemeleriyle idiyopatik AWS tanısı konuldu. Omuz, kol EHA ve progresif dirençli egzersizi, omuz fleksörlerine ve abdükörlerine germe egzersizi ve kord miyofasiyal gevşetme tedavileri uygulandı. Fiziksel modalitelerinden infrared, terapötik ultrason ve transkutanöz elektriksel sinir stimülasyonu uygulandı. Tedavi sonucunda, hastanın omuz ağrısı ve aksillerdeki kordlar geriledi, omuz EHA arttı. Omuz ağrısı ve azalmış EHA ile başvuran hastada, AWS tanısı düşünülmelidir ve detaylı omuz muayenesi yapılmalıdır. AWS'nin 1. basamak tedavisi henüz belirlenmemiştir. Belirlenmesi, erken tedavi ve böylece kronik omuz disabilitesi gelişmesini önleyecektir.

Anahtar Kelimeler: Aksiller web sendromu; lenfatik kording; omuz ağrısı; fiziksel tedavi

Axillary web syndrome (AWS) is a self terminating pain syndrome seen in breast cancer patients who have undergone axillary lymph node dissection. AWS is characterized by a web of tissue in the axillary region accompanied by pain in the ipsilateral shoulder and arm and reduced shoulder range of motion (ROM).¹ AWS has been reported to occur in approximately 50% of those who have undergone

axillary lymph node surgery.² In recent years, AWS cases unrelated to surgery have started to attract attention.^{3,4} Moreover, a couple of cases of idiopathic AWS have also been reported in the literature, to the best of our knowledge, the case described here is the third.^{5,6}

Here we present the case of a patient diagnosed with idiopathic AWS and treated with physical ther-

Correspondence: Selin OZEN

Department of Physical and Rehabilitation Medicine, Başkent University Faculty of Medicine, Ankara, TURKEY/TÜRKİYE

E-mail: drselinozen@gmail.com



Peer review under responsibility of Journal of Physical Medicine and Rehabilitation Science.

Received: 10 Mar 2021

Received in revised form: 29 Apr 2021

Accepted: 17 May 2021

Available online: 24 May 2021

1307-7384 / Copyright © 2020 Turkey Association of Physical Medicine and Rehabilitation Specialist Physicians. Production and hosting by Türkiye Klinikleri.

This is an open access article under the CC BY-NC-ND license (<https://creativecommons.org/licenses/by-nc-nd/4.0/>).

apy (PT) with good outcomes. This case highlights the importance of considering a diagnosis of AWS, even in the absence of an obvious aetiology, in the differential diagnosis of shoulder pain, and the benefits of PT in its treatment.

CASE REPORT

A 29-year-old male business manager presented to the outpatient clinic with a three day history of left shoulder pain and reduced mobility. The pain radiated to the ipsilateral arm and was exacerbated by movement, scoring 5/10 on a visual analogue scale (VAS). There was no report of neck pain or paraesthesia in the arm. There was no history of shoulder-upper extremity trauma, nor muscle strain, a review of systems was normal. A past medical history included anxiety, treated with antidepressants and discontinued six months previously, grade 2 hepatosteatosis and surgery for a pilonidal sinus. The patient was a non smoker, non drinker.

On physical examination, the patient appeared well with a body mass index of 33.03 kg/m². Inspection of the left shoulder and arm revealed a band-like subcutaneous structure in the axilla (Figure 1). On palpation, the structure consisted of three, non tender cords extending to the ipsilateral elbow.

Active left shoulder flexion and abduction were limited to 120° and 150° respectively with pain on movement; the cord became more apparent with shoulder flexion. Neck examination was normal; there were no motor-sensory deficits of the upper extremities. Disabilities of the Arm Shoulder and Hand (QDASH) assessment revealed a score of 38.3.⁷

Left shoulder ultrasonography (USG) revealed three subcutaneous hypoechoic bands 1.6 mm, 1.3 mm and 0.9 mm in diameter extending from the left

axilla to the medial side of the elbow joint (Figure 2). Doppler USG of the vascular structures was normal, with no blood flow through the cords. No pathology of the shoulder joint and periarticular structures was detected on magnetic resonance imaging (MRI). Subcutaneous oedema was present adjacent to the superomedial aspect of the humerus. Routine blood tests including erythrocyte sedimentation rate and C-reactive protein levels were also normal.

The patient was diagnosed with AWS and was administered asemetazine 60 mg twice daily for pain relief. Fifteen sessions of PT were planned: infrared (20 minutes/day), transcutaneous electrical nerve stimulation at a frequency of 100 Hz for 20 minutes, and therapeutic USG (1.5 watt/cm², 1 MHz, 5 minutes/day). This was followed by shoulder and arm ROM and strengthening exercises, stretching of the shoulder flexors and abductors and myofascial release massage of the cord. The patient was advised on a home exercise program and self massage aimed at increasing venous and lymphatic drainage.

Following the seventh PT session, the patient complained of pain in the left axilla. The next day, a small ecchymotic area appeared in the axilla (Figure 3). On palpation there were now two cords present. After completion of treatment, the patient's pain completely resolved, (VAS 0), there were no palpable cords and active shoulder ROM had returned to normal (Figure 4). The patient's QDASH score was now 7.5. No side effects of treatment occurred.

PATIENT CONSENT

Written informed consent was obtained from all patients prior to drafting of the manuscript.

DISCUSSION

To date, AWS has mostly been associated with axillary lymphadenectomy or sentinel node biopsy performed as a part of breast surgery resulting in an interruption to lymphatic and vascular flow.^{1,8} Idiopathic AWS has rarely been reported in the literature.^{5,6} These cases highlight the importance of AWS being considered in the differential diagnosis of id-

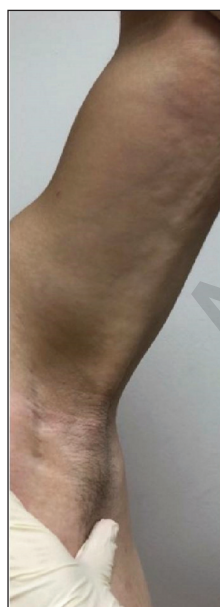

FIGURE 1: The axillary cord before treatment.

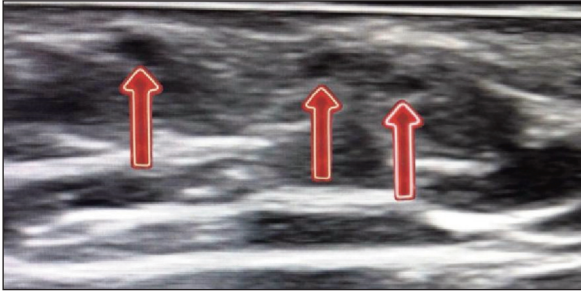


FIGURE 2: Diagnostic ultrasound imaging of the transverse view of the cord.

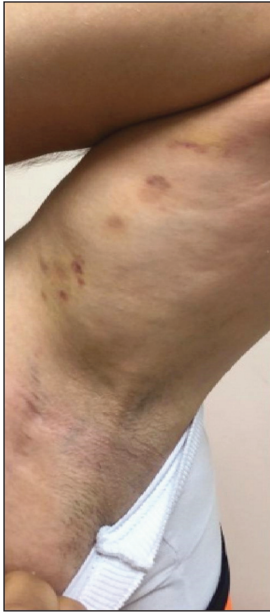

FIGURE 3: Ecchymotic areas seen following the rupture of one of the cords.

iopathic shoulder pain. Moreover, these cases emphasize the importance of inclusion of an examination of the axilla in those presenting with shoulder and arm pain; especially as patients are often unaware that they have developed a cord.²

In the case presented here, the cords were initially assessed using diagnostic USG which enables clinicians to palpate and visualise the cords simultaneously, allows for a dynamic assessment of the joint, eases

patient cooperation and is a practical tool. In the study by Leduc et al. USG was found to be more effective at identifying cords when compared to MRI.⁹ To the contrary, a pilot study concluded that USG was insufficient in identifying the cord structure.¹⁰ In our patient, the cords were not visualised on MRI. This may be due to the MRI sequences not corresponding to the cords. Further studies need to be conducted to establish the optimum imaging technique for the correct identification of the cords seen in AWS.

Studies support the use of PT in the treatment of AWS and hypothesise that PT treats the cords more rapidly than no treatment.^{11,12} This is an important

issue as reduced shoulder ROM secondary to AWS can lead to chronic shoulder immobility and weakness of the shoulder muscles. In the case presented here, the cords resolved with PT and a home exercise programme. Therapeutic USG was used alongside conventional exercises and manual fibrous release techniques. Diathermic modalities, such as therapeutic USG, heat deeper tissues, increase tissue elasticity and metabolic rate and reduce muscle pain and spasm.¹³ There is need for further evidence on the correct management approach to patients with AWS. Guidance must also account for the aetiology of AWS; PT modalities with diathermic properties, may not be appropriate for use in those in which lymphatic drainage is compromised secondary to surgery.^{14,15}

AWS is mostly seen following breast surgery but can also be seen in patients with no predisposing history or risk factors. This case highlights the need to consider a diagnosis of AWS in patients presenting with shoulder pain and reduced ROM, and the importance of a detailed shoulder examination to avoid misdiagnosis. Further studies on the optimum investigatory procedures and treatment of AWS are required to aid its timely management and avoid the development of chronic shoulder disability.

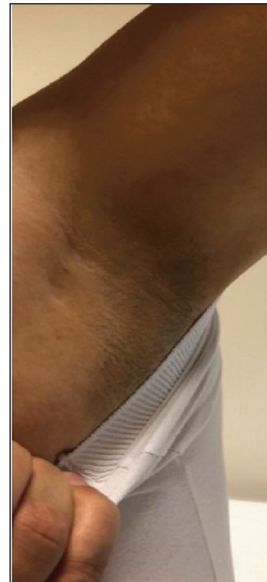

FIGURE 4: Resolution of cords following the course of physical therapy.

Bilgilendirme

Yazarlar arasında dergi editörünün isminin bulunması nedeniyle, ilgili çalışmanın değerlendirme süreci konuk editör tarafından yürütülmüştür.

Informing

Due to the presence of the name of the journal editor's among the authors, the assessment process of the study was conducted by the guest editor.

REFERENCES

1. Moskovitz AH, Anderson BO, Yeung RS, et al. Axillary web syndrome after axillary dissection. *Am J Surg*. 2001;181:434-9. PMID: 11448437
2. Koehler LA, Hunter DW, Blaes AH, et al. Function, shoulder motion, pain, and lymphedema in breast cancer with and without axillary web syndrome: an 18-month follow-up. *Phys Ther*. 2018;98:518-27. PMID: 29361075; PMCID: PMC6692645
3. Welsh P, Gryfe D. Atypical presentation of axillary web syndrome (AWS) in a male squash player: a case report. *J Can Chiropr Assoc*. 2016;60:294-8. PMID: 28065989; PMCID: PMC517 8020
4. Hunt WTN, Porter R, Lucke T. Axillary web syndrome induced by physical exertion. *Clin Exp Dermatol*. 2020;45:382-4. PMID: 3153 8359
5. Demir Y, Güzelküçük Ü, Kesikburun S, et al. A rare cause of shoulder pain: axillary web syndrome. *Turk J Phys Med Rehabil*. 2018; 63:178-80. PMID: 31453448; PMCID: PMC6648119
6. Tetik B, Songür K, Aşkın A. [Axillary web syndrome: an overlooked cause of shoulder pain]. *Cukurova Med J*. 2019;44:255-9. <https://dergipark.org.tr/tr/download/article-file/640334>
7. Beaton DE, Katz JN, Fossel AH, et al. Measuring the whole or the parts? Validity, reliability, and responsiveness of the Disabilities of the Arm, Shoulder and Hand outcome measure in different regions of the upper extremity. *J Hand Ther*. 2001;14:128-46. PMID: 11382 253
8. Leidenius M, Leppänen E, Krogerus L, et al. Motion restriction and axillary web syndrome after sentinel node biopsy and axillary clearance in breast cancer. *Am J Surg*. 2003;185:127-30. PMID: 12559441
9. Leduc O, Fumière E, Banse S, et al. Identification and description of the axillary web syndrome (AWS) by clinical signs, MRI and US imaging. *Lymphology*. 2014;47:164-76. PMID: 25915977
10. O'Toole J, Hannon K, Skolny MN, et al. The role of sonographic imaging to assess the pathophysiology of cording in patients treated for breast cancer: a pilot study. *J Diagn Med Sonogr*. 2015;31:276-81. <https://journals.sagepub.com/doi/pdf/10.1177/87564793.15599540>
11. Josenhans E. Physiotherapeutic treatment for axillary cord formation following breast cancer surgery. *Pt Zeitschrift für Physiother*. 2007; 59:868-78. https://praxisjosenhans.de/wp-content/uploads/2014/04/Arbeit_Wissenschaftspreis_english.pdf
12. Fourie WJ, Robb KA. Physiotherapy management of axillary web syndrome following breast cancer treatment: discussing the use of soft tissue techniques. *Physiotherapy*. 2009; 95:314-20. PMID: 19892098
13. Miller DL, Smith NB, Bailey MR, et al; Bioeffects Committee of the American Institute of Ultrasound in Medicine. Overview of therapeutic ultrasound applications and safety considerations. *J Ultrasound Med*. 2012;31: 623-34. PMID: 22441920; PMCID: PMC38 10 427
14. Rockson SG. Precipitating factors in lymphedema: myths and realities. *Cancer*. 1998;83:2814-6. PMID: 9874403
15. Chevillat AL, Tchou J. Barriers to rehabilitation following surgery for primary breast cancer. *J Surg Oncol*. 2007;95:409-18. PMID: 174 57830