

# Using Handheld Portable Ultrasound in Bedside Assessment of Post-stroke Hemiplegic Shoulders: Early Detection of Glenohumeral Subluxation

## İnme Sonrası Hemiplejik Omuzların Yatak Başı Değerlendirilmesinde El Tipi Taşınabilir Ultrasonun Kullanılması: Glenohumeral Subluksasyonun Erken Tespiti

 Yakup ERDEN<sup>a</sup>,  Muhammed KORKUT<sup>a</sup>

<sup>a</sup>İzzet Baysal Physical Treatment and Rehabilitation Training and Research Hospital, Clinic of Physical Medicine and Rehabilitation, Bolu, Türkiye

**ABSTRACT** Handheld ultrasound devices has enabled more practical scanning in various environments and conditions for all physicians. Bedside ultrasonography may facilitate early diagnosis and ease of follow-up especially in patients with restricted mobility. Early detection and effective treatment of shoulder subluxation in post-stroke patients may contribute to the recovery process.

**ÖZET** Elde taşınabilir ultrason cihazları, tüm hekimler için çeşitli ortam ve koşullarda daha pratik tarama yapılmasına olanak sağlamıştır. Yatak başı ultrasonografi, özellikle hareket kısıtlılığı olan hastalarda erken tanı ve takip kolaylığı sağlayabilir. İnme sonrası hastalarda da omuz subluksasyonunun erken tespiti ve etkili tedavisi iyileşme sürecine katkıda bulunabilir.

The role of ultrasound (US) imaging in the diagnosis and treatment of musculoskeletal disorders is now better known by physicians. In recent years, portable US devices have become more popular and have reached daily practice. The recent development of wireless US transducers has led to more practical scanning in various environments and conditions.<sup>1</sup> In this context, this letter aims to address the role of handheld US in the bedside evaluation of poststroke patients with shoulder subluxation.

Hemiplegic shoulder subluxation after stroke is seen between 17% and 84%. The development of shoulder subluxation occurs mostly during the first 3

weeks of hemiplegia. The incidence increases in patients with flaccid hemiplegia and patients with greater motor impairment.<sup>2</sup> Since shoulder subluxation may affect the rehabilitation process, it is recommended to detect it as early as possible and treat it effectively. Various methods have been developed to measure shoulder subluxation in hemiplegia. Clinical and radiologic methods are currently used to evaluate glenohumeral subluxation. The clinical methods can be applied quickly and do not require equipment, but they lack the ability to detect minor subluxation early (differences of <5 mm) and are subjective. Radiography provides an objective measurement, but

**TO CITE THIS ARTICLE:**

Erden Y, Korkut M. Using Handheld Portable Ultrasound in Bedside Assessment of Post-stroke Hemiplegic Shoulders: Early Detection of Glenohumeral Subluxation. Türkiye Klinikleri Journal of Physical Medicine and Rehabilitation Sciences. 2024;27(2):144-6.

**Correspondence:** Yakup ERDEN

İzzet Baysal Physical Treatment and Rehabilitation Training and Research Hospital, Clinic of Physical Medicine and Rehabilitation, Bolu, Türkiye

**E-mail:** yakuperden@hotmail.com



Peer review under responsibility of Journal of Physical Medicine and Rehabilitation Science.

**Received:** 04 Dec 2023

**Received in revised form:** 19 Feb 2024

**Accepted:** 26 Feb 2024

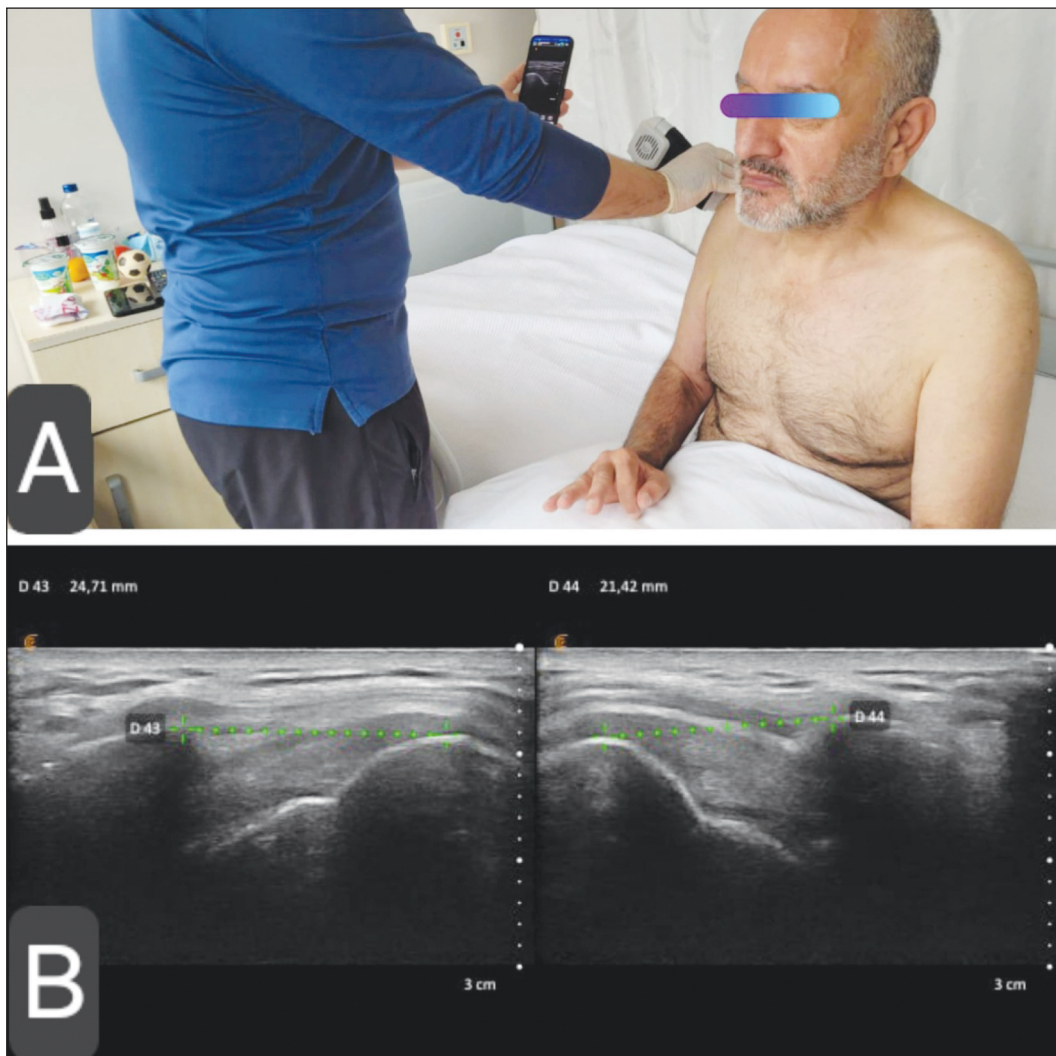
**Available online:** 04 Mar 2024

1307-7384 / Copyright © 2024 Turkey Association of Physical Medicine and Rehabilitation Specialist Physicians. Production and hosting by Türkiye Klinikleri.

This is an open access article under the CC BY-NC-ND license (<https://creativecommons.org/licenses/by-nc-nd/4.0/>).

patients are exposed to radiation. Since it is shot in a single plane, it is insufficient to evaluate variations.<sup>3</sup> Magnetic resonance imaging (MRI) allows for multiplanar imaging in anatomic planes, but it is difficult to perform shoulder in stroke patients with hemiplegia because of the limited and intolerable positioning of the patients. The patients may have difficulty in maintaining the required supine and neutral position during MRI.<sup>4</sup> Ultrasonography is another diagnostic tool to quantify the degree of shoulder subluxation in poststroke hemiplegia.<sup>5</sup> Sonography, especially with wireless devices, provides quick and real-time imaging by easily positioning the patient at the bedside.

The method utilizes the measurement of acromion-greater tuberosity (AGT) distance (mm) for the assessment of subluxation. While the patient is in a sitting position with both hips and knees flexed to 90 degrees and feet flat on the floor, the shoulder is placed in neutral, the elbow is flexed, and the forearm is pronated. Without supporting the elbow joint itself, the forearms rest on a pillow placed on the patient's lap. Once in this position, the US image capturing the lateral border of the acromion and the superior part of the greater tuberosity of the humerus is frozen and the distance between these two bony reference points is measured (Figure 1).<sup>6</sup> The asym-



**FIGURE 1:** A) Bedside position of patients for ultrasonographic measurements of AGT distance; B) Coronal superiolateral B-scan of both shoulders showing AGT distance between the lateral border of the acromion and the nearest superior margin of the greater tuberosity. AGT difference between affected (24.71 mm) and unaffected shoulder (21.42 mm) is 3.29 mm (>2 mm), indicating subluxation.

AGT: Acromion-greater tuberosity.

metry of the cut-off value  $\geq 2$  mm between affected and unaffected shoulders suggests minor subluxation.<sup>3</sup> The measurements of AGT distance demonstrated good intra-rater and inter-rater reliability among stroke patients.<sup>7</sup> Soft tissue alterations associated with the subluxation can also be detected simultaneously with ultrasonography.<sup>8</sup>

Modern handheld US devices are contributing to make bedside US evaluation, a practice available to all physicians. Bedside US may facilitate early diagnosis and ease of follow-up especially in patients with restricted mobility. Due to its easy application and diagnostic reliability, wireless US machines can represent a valuable imaging method for the primary assessment of hemiplegic shoulder findings.

### **Source of Finance**

*During this study, no financial or spiritual support was received neither from any pharmaceutical company that has a direct connection with the research subject, nor from a company that provides or produces medical instruments and materials which may negatively affect the evaluation process of this study.*

### **Conflict of Interest**

*No conflicts of interest between the authors and / or family members of the scientific and medical committee members or members of the potential conflicts of interest, counseling, expertise, working conditions, share holding and similar situations in any firm.*

### **Authorship Contributions**

*All authors contributed equally while this study preparing.*

## REFERENCES

1. Bağcıer F, Yurdakul OV. Using wireless ultrasound during pandemic: Less contact may be the better. *Agri*. 2022;34:322-3. English. [[Crossref](#)] [[PubMed](#)]
2. Stolzenberg D, Siu G, Cruz E. Current and future interventions for glenohumeral subluxation in hemiplegia secondary to stroke. *Top Stroke Rehabil*. 2012;19:444-56. [[Crossref](#)] [[PubMed](#)]
3. Kumar P, Mardon M, Bradley M, et al. Assessment of glenohumeral subluxation in poststroke hemiplegia: comparison between ultrasound and finger-breadth palpation methods. *Phys Ther*. 2014;94:1622-31. [[Crossref](#)] [[PubMed](#)]
4. El-Sonbaty HAE, Abou Elmaaty AA, Zarad CA, et al. Clinical and radiological assessment of hemiplegic shoulder pain in stroke patients. *Egypt J Neurol Psychiatry Neurosurg*. 2022;58:41. [[Crossref](#)]
5. Park GY, Kim JM, Sohn SI, et al. Ultrasonographic measurement of shoulder subluxation in patients with post-stroke hemiplegia. *J Rehabil Med*. 2007;39:526-30. [[Crossref](#)] [[PubMed](#)]
6. Kumar P, Bradley M, Gray S, et al. Reliability and validity of ultrasonographic measurements of acromion-greater tuberosity distance in post-stroke hemiplegia. *Arch Phys Med Rehabil*. 2011;92:731-6. [[Crossref](#)] [[PubMed](#)]
7. Kumar P, Cruziah R, Bradley M, et al. Intra-rater and inter-rater reliability of ultrasonographic measurements of acromion-greater tuberosity distance in patients with post-stroke hemiplegia. *Top Stroke Rehabil*. 2016;23:147-53. [[Crossref](#)] [[PubMed](#)]
8. Lee IS, Shin YB, Moon TY, et al. Sonography of patients with hemiplegic shoulder pain after stroke: correlation with motor recovery stage. *AJR Am J Roentgenol*. 2009;192:W40-4. [[Crossref](#)] [[PubMed](#)]