

# Foot Drop Following Bariatric Surgery: A Case Report

## Bariatrik Cerrahi Sonrası Gelişen Düşük Ayak: Olgu Sunumu

 Deniz SARITOSUN<sup>a</sup>,  Selda ÇİFTÇİ İNCEOĞLU<sup>a</sup>,  Banu KURAN<sup>a</sup>

<sup>a</sup>Health Sciences University İstanbul Şişli Hamidiye Etfal Training and Research Hospital,  
Clinic of Physical Medicine and Rehabilitation, İstanbul, Türkiye

**ABSTRACT** The aim of this case report is to present a case of peroneal neuropathy after bariatric surgery and review the literature. The patient, who underwent bariatric surgery due to obesity, developed neuropathic complaints in his right foot approximately 7 months after the operation. A few days later, he applied to our out-patient clinic because of weakness. It was learned that she lost 30 kg after the operation. Peroneal neuropathy was considered in the physical examination, and peroneal entrapment was detected in the fibular head in the requested electromyography examination. The patient was included in the physical therapy and rehabilitation program. The patient's complaints decreased and muscle strength returned to the normal level. After bariatric surgery, optimal nutritional care should be taken and controlled weight loss should be ensured. If neurological complications develop, appropriate treatment should be initiated.

**Keywords:** Bariatric surgery; complication; foot drop; peroneal neuropathy; weight loss

**ÖZET** Bu olgu sunumunun amacı, bariatrik cerrahi sonrası peroneal nöropati olgusunu sunmak ve literatürü gözden geçirmektir. Obezite nedeniyle bariatrik cerrahi geçiren hastada, operasyondan yaklaşık 7 ay sonra sağ ayağında nöropatik şikâyetler gelişmişti. Birkaç gün sonrasında güçsüzlük nedeniyle polikliniğimize başvurmuştu. Operasyondan sonra 30 kilo verdiği öğrenildi. Fizik muayenede peroneal nöropati düşünüldü ve istenen elektromiyografi incelemesinde fibula başında peroneal tuzaklanma tespit edildi. Hasta fizik tedavi ve rehabilitasyon programına alındı. Hastanın şikâyetleri azaldı ve kas gücü normale döndü. Bariatrik cerrahi sonrası optimal beslenme bakımı yapılmalı ve kontrollü kilo kaybı sağlanmalıdır. Nörolojik komplikasyonlar gelişirse uygun tedavi başlanmalıdır.

**Anahtar Kelimeler:** Bariatrik cerrahi; komplikasyon; düşük ayak; peroneal nöropati; kilo kaybı

Obesity is becoming increasingly widespread, and the risk of diseases such as cardiovascular diseases, osteoarthritis, cancer, hypertension and diabetes mellitus is increasing.<sup>1</sup> Bariatric surgery (BS) is also a method used in the treatment of obesity to reduce serious morbidities and mortality and to maintain quality of life.<sup>2</sup> Today, the most commonly used methods are sleeve gastrectomy, vertical gastropasty, gastric bypass, gastric banding and duodenal switch.

However, rapid weight loss due to these procedures may lead to complications.<sup>1</sup>

Peripheral neuropathies (PN) are more common after BS than central nervous system complications. Neurological complications due to BS may be seen in the early perioperative period or weeks, months, or years later.<sup>3</sup> PN may develop due to rapid weight loss and the decrease in fat tissue around the fibular head.<sup>4</sup>

**TO CITE THIS ARTICLE:**

Santosun D, Çiftçi İnceoğlu S, Kuran B. Foot Drop Following Bariatric Surgery: A Case Report. Türkiye Klinikleri Journal of Physical Medicine and Rehabilitation Sciences. 2025;228(2):191-4.

**Correspondence:** Selda ÇİFTÇİ İNCEOĞLU

Health Sciences University İstanbul Şişli Hamidiye Etfal Training and Research Hospital,  
Clinic of Physical Medicine and Rehabilitation, İstanbul, Türkiye

**E-mail:** seldavd@gmail.com



Peer review under responsibility of Journal of Physical Medicine and Rehabilitation Science.

**Received:** 25 Nov 2024

**Received in revised form:** 04 Jan 2025

**Accepted:** 20 Jan 2025

**Available online:** 29 Jan 2025

1307-7384 / Copyright © 2025 Turkey Association of Physical Medicine and Rehabilitation Specialist Physicians. Production and hosting by Türkiye Klinikleri.

This is an open access article under the CC BY-NC-ND license (<https://creativecommons.org/licenses/by-nc-nd/4.0/>).

In this case report, it is aimed to review the literature by discussing a case of peroneal neuropathy after BS and appropriate diagnostic and rehabilitation approaches.

## CASE REPORT

A 50-year-old woman with a long-term history of obesity and previously diagnosed asthma and diabetes mellitus underwent a sleeve gastrectomy operation with 93 kg weight and 34.5 kg/m<sup>2</sup> Body Mass Index (BMI) of 34.5 kg/m<sup>2</sup> on November 2023. She was on daily collagen capsules and a combined multivitamin preparation [500 mg thiamine HCl (thiamine hydrochloride) (vitamin B<sub>1</sub>), 5 mg pyridoxine HCl (vitamin B<sub>6</sub>) and 1 mg cyanocobalamin (vitamin B<sub>12</sub>)] after the surgery. The patient did not consume alcohol and had a 2-pack/year smoking history. She lost 30 kg during the follow-up. She stated that she had kept doing habitual leg crossing. 7 months after the operation, she started feeling tingling and paresthesia around the anterior side of her right knee and lower leg. A few days after the tingling sensations had started, she had weakness on her right foot. She applied to our out-patient clinic with her current complaints.

## PHYSICAL EXAMINATION

In the physical examination, the patient showed the obvious right-sided global weakness of the muscles for ankle dorsiflexion, plantar flexion, eversion, inversion and big toe extension (right: 2/5 and left: 5/5). The strength of the other muscles was normal. There was no detectable loss of sensation around the calf or the foot. The peripheral pulses in the right lower extremity were palpable. The upper and lower extremity deep tendon reflexes were normal. The Babinski responses were bilateral flexor.

## LABORATORY EXAMINATIONS

Glucose was 91 mg/dL, creatinine was 0.72 mg/dL, thyroid-stimulating hormone was 3.37 mIU/L, T4 was 0.8 ng/L, T3 was 3.12 ng/L, vitamin B<sub>12</sub> was 286 ng/L, folate was 11 mcg/L and other laboratory parameters were also within normal limits. No laboratory findings that could cause peroneal neuropathy were detected.

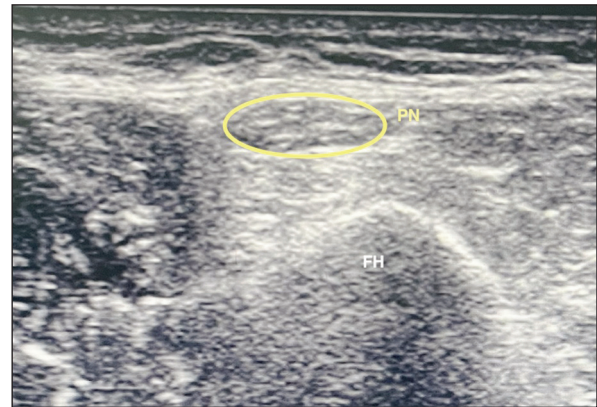


FIGURE 1: Peroneal nerve on the fibular head with ultrasound.

FH: fibular head; PN: peroneal nerve.

## IMAGING EXAMINATIONS

There were no findings that would explain the foot-drop symptom on Magnetic resonance imaging (MRI) study of the lumbar spine that was performed to rule out the possibility of lumbosacral lesions. Ultrasonography revealed no tumors or cysts along the course of the sciatic nerve and peroneal nerve from the hip to the lower leg (Figure 1). When we evaluated the fibular nerve cross-sectional area at the level of the bilateral fibular head, we found it to be 12.3 mm<sup>2</sup> on the right and 9.1 mm<sup>2</sup> on the left. On the right knee and right cruris MRI, no structure was found around the fibular head that could cause entrapment of the peroneal nerve.

## ELECTROMYOGRAPHY (EMG) EXAMINATION

The patient was then scheduled for an electromyography (EMG) appointment on the 8th month after the sleeve gastrectomy operation. The bilateral peroneal superficial and sural sensory nerve conduction studies and tibial motor nerve conduction studies were found to be normal. In motor conduction studies performed with recordings from the right extensor digitorum brevis (EDB), a 50% decrease in peroneal nerve response amplitude, delay in latency, and decrease in conduction velocity were detected above the knee level compared with the distal (ankle/fibular head/knee amplitude 4.5/3.8/2.1 mV, latency 3.30/9.10/11.25 ms, fibular head/knee velocity 55.2/37.2 m/s, respectively). Again, the peroneal

nerve motor response amplitude recorded from the tibialis anterior (TA) was obtained lower with proximal stimulation than with distal stimulation (fibular head/knee amplitude 4.1/1.1 mV). In the needle EMG study, widespread denervation findings were seen in the TA and extensor hallucis longus (EHL) muscles, and motor unit potentials were found to have normal duration and amplitude but were very twitched. In addition, no chronic compression findings were detected at the L5 root.

## REHABILITATION

The patient used an ankle-foot orthosis for 1 month to reduce the risk of falling. Transcutaneous electrical nerve stimulation for 20 min, hot pack for 20 min, and pulsed US around the right fibular head for 8 min were applied as physical therapy modalities for the patient's pain. Passive and active assisted range of motion exercises and a personalized exercise program were shown to the patient with the help of a physiotherapist. Neuromuscular electrical stimulation was applied to the tibialis anterior and peroneal muscles. Afterwards, strengthening exercises were also started. A total of 15 sessions of physical therapy and an exercise program were applied. Improvement was observed in the patient's muscle strength, and the use of the orthosis was discontinued. In the 4<sup>th</sup> month follow-up after the completion of the physical therapy program, only the EHL muscle strength on the right was 4+/5, while the TA and EDB muscle strength were 5/5. The patient was satisfied with the treatment and had no additional complaints. Written and verbal consent was obtained from the patient for the case presentation.

## DISCUSSION

The common peroneal nerve emerges from the sciatic nerve and travels around the fibular neck. The area around the fibular head is not protected by muscles or soft tissue and is very thin, which makes the peroneal nerve around this area prone to damage, which makes PN a common mononeuropathy.<sup>5,6</sup> The first person who reported the relationship between weight loss and foot drop was Woltman in 1929.<sup>7</sup> A study that was done in 2000's shows that peroneal neuropathy accounts for 15% of all mononeuropathic in adults.<sup>8</sup> Since then, there have been many cases

about the relationship between peroneal neuropathy and weight loss, such as diets, malnutrition, anorexia, and severe diseases including malignancies.<sup>9-11</sup> Additionally, cases of PN have been reported in abdominal surgery that causes rapid weight loss other than BS.<sup>12</sup> Even though its correlation with weight loss has not fully determined yet, PN has been shown to develop in 26 (7%) of 393 patients with BS.<sup>13</sup>

It is still not fully understood what mechanisms of weight loss cause PN; nevertheless, there are several hypotheses. One hypothesis is that rapid weight loss can result in decreased adipose tissue around the fibular head, which makes the peroneal nerve that was already prone to damage more vulnerable to the after effects of compression.<sup>14</sup> Another hypothesis is that rapid weight loss causes a nutritional deficit that results in neuropathy.<sup>15</sup>

There are studies in the literature that support different treatment approaches. The conservative treatments include physical therapy, vitamin and nutritional support.<sup>16</sup> For patients who do not respond to conservative treatment, surgical treatment is planned before irreversible neurological damage occurs.<sup>17</sup> Weyns et al. suggested that surgery was indicated if there was no evidence of functional improvement within 3 weeks after conduction block across the fibular head in PN.<sup>18</sup> One of the previous studies showed that 29 of 30 patients with PN-associated weight loss recovered within 3 weeks to 3 months, and only one patient needed surgical intervention and recovered at six months after surgery.<sup>8</sup> However, to understand and compare the benefits of conservative and surgical treatment, long-term follow-up studies and large population groups are required.

In contrast to neuropathies following BS, one study has shown that improvement in triglyceride levels protects against early small nerve fiber degeneration.<sup>19</sup> This shows us that high-evidence studies are needed on neuropathies after BS.

In conclusion, BS is an effective treatment for obesity and prevents many comorbidities and mortality. However, attention should be paid to peroneal neuropathy, which is one of the complications that may occur after the operation, and appropriate treatment and follow-up should be performed.

### Source of Finance

During this study, no financial or spiritual support was received neither from any pharmaceutical company that has a direct connection with the research subject, nor from a company that provides or produces medical instruments and materials which may negatively affect the evaluation process of this study.

### Conflict of Interest

No conflicts of interest between the authors and / or family members of the scientific and medical committee members or members

of the potential conflicts of interest, counseling, expertise, working conditions, share holding and similar situations in any firm.

### Authorship Contributions

**Idea/Concept:** Deniz Saritosun, Selda Çiftci İnceoğlu; **Design:** Deniz Saritosun, Selda Çiftci İnceoğlu; **Control/Supervision:** Selda Çiftci İnceoğlu, Banu Kuran; **Data Collection and/or Processing:** Deniz Saritosun, Selda Çiftci İnceoğlu; **Literature Review:** Selda Çiftci İnceoğlu; **Writing the Article:** Deniz Saritosun, Selda Çiftci İnceoğlu; **Critical Review:** Banu Kuran.

## REFERENCES

1. Fares MY, Dimassi Z, Fares J, et al. Peroneal neuropathy and bariatric surgery: untying the knot. *Int J Neurosci.* 2020;130(4):417-23. [[Crossref](#)] [[PubMed](#)]
2. Landais A. Neurological complications of bariatric surgery. *Obes Surg.* 2014;24(10):1800-7. [[Crossref](#)] [[PubMed](#)]
3. Goodman JC. Neurological complications of bariatric surgery. *Curr Neurol Neurosci Rep.* 2015;15(12):79. [[Crossref](#)] [[PubMed](#)]
4. Lale A, Kirkil C, Ozturk S, Yur M, Can OF, et al. The results of surgical decompression in the treatment of foot drop due to peroneal nerve entrapment after bariatric surgery. *Surg Obes Relat Dis.* 2020;16(11):1684-91. [[Crossref](#)] [[PubMed](#)]
5. Tsukamoto H, Granata G, Coraci D, et al. Ultrasound and neurophysiological correlation in common fibular nerve conduction block at fibular head. *Clin Neurophysiol.* 2014;125(7):1491-5. [[Crossref](#)] [[PubMed](#)]
6. Desai SLJ. Common peroneal nerve palsy in maxillofacial surgery setting. *Natl J Maxillofac Surg.* 2017;8(1):85-6. [[Crossref](#)] [[PubMed](#)] [[PMC](#)]
7. Woltman HW. Crossing the legs as a factor in the production of peroneal palsy. *Journal of the American Medical Association.* 1929;93(9):670-2. [[Crossref](#)]
8. Cruz-Martinez A, Arpa J, Palau F. Peroneal neuropathy after weight loss. *J Peripher Nerv Syst.* 2000;5(2):101-5. [[Crossref](#)] [[PubMed](#)]
9. Sotaniemi KA. Slimmer's paralysis—peroneal neuropathy during weight reduction. *J Neurol Neurosurg Psychiatry.* 1984;47(5):564-6. [[Crossref](#)] [[PubMed](#)] [[PMC](#)]
10. Shahar E, Landau E, Genizi J. Adolescence peroneal neuropathy associated with rapid marked weight reduction: case report and literature review. *Eur J Paediatr Neurol.* 2007;11(1):50-4. [[Crossref](#)] [[PubMed](#)]
11. Denny-Brown D. Neurological conditions resulting from prolonged and severe dietary restriction; case reports in prisoners-of-war, and general review. *Medicine (Baltimore).* 1947;26(1):41-113. [[Crossref](#)] [[PubMed](#)]
12. Oh MW, Gu MS, Kong HH. Bilateral common peroneal neuropathy due to rapid and marked weight loss after biliary surgery: a case report. *World J Clin Cases.* 2021;9(8):1909-15. [[Crossref](#)] [[PubMed](#)] [[PMC](#)]
13. Thaisetthawatkul P, Collazo-Clavell ML, Sarr MG, et al. Good nutritional control may prevent polyneuropathy after bariatric surgery. *Muscle Nerve.* 2010;42(5):709-14. [[Crossref](#)] [[PubMed](#)] [[PMC](#)]
14. Meylaerts L, Cardinaels E, Vandevenne J, et al. Peroneal neuropathy after weight loss: a high-resolution ultrasonographic characterization of the common peroneal nerve. *Skeletal Radiol.* 2011;40(12):1557-62. [[Crossref](#)] [[PubMed](#)]
15. San Martin GG, Pérez Moro OS, Fernández-Cuadros ME. Nerve Compression secondary to weight loss. *Int J Neurorehabilitation Eng.* 2016;3(3). [[Crossref](#)]
16. Ramos-Levi AM, Matias-Guiu JA, Guerrero A, et al. Peroneal palsy after bariatric surgery; is nerve decompression always necessary? *Nutr Hosp.* 2013;28(4):1330-2. [[Crossref](#)] [[PubMed](#)]
17. Lin IC, Lin YL. Peripheral polyneuropathy after bariatric surgery for morbid obesity. *J Family Community Med.* 2011;18(3):162-4. [[Crossref](#)] [[PubMed](#)] [[PMC](#)]
18. Weyns FJ, Beckers F, Vanormelingen L, Vandersteen M, Niville E. Foot drop as a complication of weight loss after bariatric surgery: is it preventable? *Obes Surg.* 2007;17(9):1209-12. [[Crossref](#)] [[PubMed](#)]
19. Azmi S, Ferdousi M, Liu Y, Adam S, et al. Bariatric surgery leads to an improvement in small nerve fibre damage in subjects with obesity. *Int J Obes (Lond).* 2021;45(3):631-8. [[Crossref](#)] [[PubMed](#)]